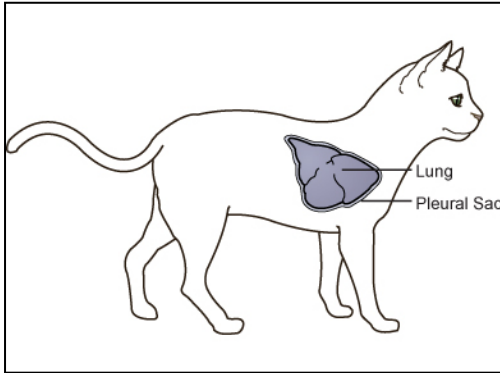


Pleural Effusion

What is a pleural effusion?

A pleural effusion refers to an accumulation of fluid within the pleural cavity. This fluid is usually located within the pleural sac which is a serous membrane covering the lungs.



The pleural sac can be thought of as a “plastic wrap” around the lungs that can potentially hold fluid or air (a potential space). It normally contains only a small amount of fluid, sufficient to keep the lung surfaces slippery and prevent them from sticking to the chest wall. When excess fluid enters this space, it compresses the lungs so that they cannot fully expand and results in impaired breathing. Some people refer to this as “chest fluid”. It must be emphasized that a pleural effusion involves fluid on the **outside** or surrounding the lungs, not within the

lung tissues.

What are the clinical signs of pleural effusions?

Clinical signs are related to the specific cause of the fluid accumulation but most commonly include:

- Loss of appetite
- Lethargy
- Dyspnea (labored or difficulty breathing)
- Tachypnea (increased respiratory rate)
- Orthopnea (difficulty breathing except in the upright position)
- Cyanosis (bluish discoloration of skin and mucous membranes)
- Exercise intolerance
- Respiratory distress
- Open-mouth breathing

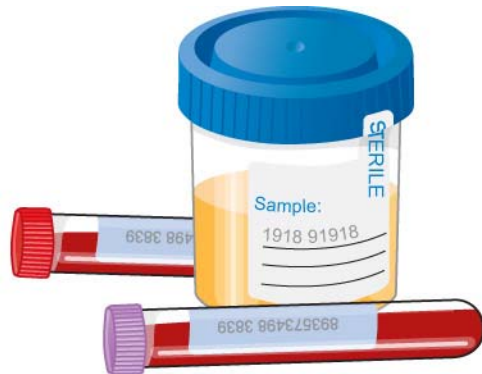
Many cats will present with open-mouth, rapid breathing. We often observe the effort to breathe in is much greater than the effort to breathe out. Most cats are displaying abdominal breathing where their abdomen is moving in and out in an attempt to maximize the expansion of the lungs. There are often decreased and muffled lung sounds on auscultation of the chest (listening with a stethoscope). When the chest is percussed (tapped with the finger while listened to with a stethoscope), there is usually dullness (decreased sound) present in the areas of fluid accumulation.

What causes a pleural effusion?

There are numerous causes for fluid accumulation in the pleural space. Some of the general causes are:

- Higher than normal production of fluid
- Less than normal resorption of fluid
- Increased hydrostatic pressure caused by congestive heart failure (CHF), overhydration, or a tumor within the chest cavity
- Decreased oncotic pressure from hypoalbuminemia (low blood protein) secondary to protein-losing enteropathy (intestinal disease), protein-losing nephropathy (kidney disease) or liver disease)
- Changes in vascular permeability or lymphatic function
- Bacterial, viral or fungal infection
- Neoplasia – especially lymphosarcoma (LSA), thymoma, mesothelioma, primary lung tumor, or metastatic disease (cancer that has spread to the chest cavity from elsewhere in the body)
- Chylothorax (accumulation of chyle, a lymphatic fluid that originates in the intestines and has a high concentration of fat) –caused by thoracic lymphangiectasia (swollen lymph vessels that leak chyle into the pleural space), congestive heart failure, cranial vena cava obstruction, neoplasia, fungal infection, feline heartworm infection (dirofilariasis), diaphragmatic hernia, lung lobe torsion, and trauma
- Diaphragmatic hernia
- Hemothorax (bleeding into the pleural space) secondary to trauma, neoplasia, or clotting or bleeding disorder
- Lung lobe torsion (twisting of a lung lobe)
- Pulmonary thromboembolism (a blood clot in the lungs)
- Pancreatitis

Perhaps the most commonly diagnosed cause of pleural effusion in cats is chylothorax. The exact cause of chylothorax is usually unknown (called idiopathic chylothorax).



How is the condition diagnosed?

Diagnosis is based on medical history and clinical signs, the presence of fluid in the chest cavity on thoracocentesis (also known as a chest tap), chest radiographs and chest ultrasound. Blood and urine tests are often performed to look for any underlying infectious or systemic disease that is causing the fluid accumulation. The fluid removed from the chest cavity is analyzed for clues as to the origin or cause.

What is the treatment for pleural effusion?

Pleural effusion is a medical emergency and should be treated aggressively as soon as clinical signs occur. Cats have limited ability to handle any condition that compromises their breathing and often deteriorate or decompensate quickly.

The first objective of treatment is removal of the fluid compressing the lungs to allow for more normal lung expansion. This is accomplished by thoracocentesis. Oxygen therapy is often begun upon admission to the hospital if the patient needs to be stabilized prior to performing thoracocentesis. Long-term management is based on the specific cause of the fluid accumulation but includes periodic thoracocentesis, surgery such as thoracic duct ligation, and feeding special low-fat diets or supplements.

What is the prognosis for a cat diagnosed with pleural effusion?

The prognosis will be based on the specific diagnosis and response to initial treatment. A guarded prognosis is always given when initially confronted with a cat experiencing open-mouth breathing. Most cats with chylothorax have a good but guarded longterm prognosis provided the owner complies with the veterinarian's instructions.

*This client information sheet is based on material written by Ernest Ward, DVM
© Copyright 2005 Lifelearn Inc. Used with permission under license. May 16, 2014*