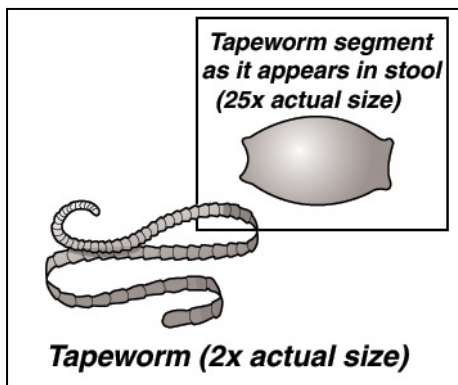


## Tapeworms in Dogs

### **What are tapeworms?**

Tapeworms are flattened intestinal worms that are made up of many small segments, each about  $\frac{1}{4}$  –  $\frac{1}{2}$  inch (3-5 mm) long. Unlike roundworms that live freely in the intestinal tract, tapeworms attach to the wall of the small intestine by hook-like mouthparts.



The most common tapeworm of dogs and cats is *Dipylidium caninum*. The adult worms may reach up to 8 inches (20 cm) in length. The individual segments are developed from the head end and gradually mature, finally being shed at the opposite end, either singly or in short chains. These segments are passed in the feces when the dog defecates. They are about  $\frac{1}{8}$ " (3 mm) long and look like grains of rice or cucumber seeds. Occasionally they can be seen moving on the hairs around the anus or on freshly passed feces. As the tapeworm segment dries, it becomes a golden color and the fertilized eggs are

released into the environment.

Unlike roundworms, dogs cannot become infected by eating fertilized tapeworm eggs. Tapeworms must first pass through an intermediate host, a flea, before they can infect a dog or cat.

### **How do dogs get tapeworms?**

When the infected eggs are released into the environment, they have to be swallowed by immature flea larvae in the environment. Once inside the larval stage of the flea, the tapeworm egg continues to develop into an infective tapeworm as the flea matures into an adult flea. During grooming or in response to a flea's bite, the dog can ingest the flea carrying the infective tapeworm and the life cycle is completed.

### **Are tapeworms dangerous for my dog?**

Tapeworms do not normally cause serious health problems in dogs. Occasionally dogs will drag their bottoms on the ground scooting in order to allay this irritation but this behavior can be for other reasons such as impacted anal sacs.

In puppies, heavy tapeworm infestation can be more serious. Lack of growth, anemia and intestinal blockage can occur. Occasionally, the head of the tapeworm or *scolex* detaches from the intestinal wall. The worm can then be passed either in the feces or vomited.

### ***How is diagnosis made?***

Clinical diagnosis is usually made by observing the white mobile tapeworm segments in the feces or crawling around the anus. They often look like grains of rice.

Tapeworm segments are only passed intermittently and therefore are often not diagnosed on routine fecal examination. If you find any segments, white or golden color, bring these to us for a definitive diagnosis.

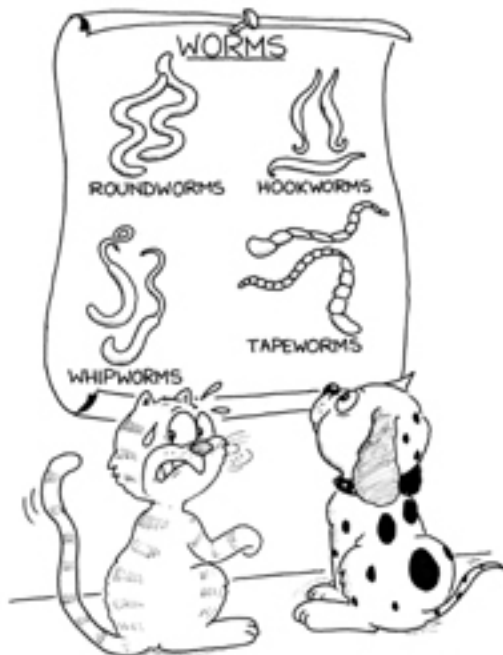
### ***What is the treatment?***

With today's drugs, treatment is safe, simple and effective. The parasiticide may be given either in the form of tablets or by injection. It causes the parasite to dissolve in the intestines so you normally will not see tapeworms passed in the stool.

These drugs are very safe and should not cause vomiting or diarrhea or other adverse side effects.

### ***Is there anything else I should do?***

Flea control is critical in the management and prevention of tapeworm infection. Flea control involves treatment of your dog and the environment. Your veterinarian can recommend safe and effective flea control for your pet. If your dog lives in a flea-infested environment, re-infection with tapeworms may occur in as little as two weeks. Since tapeworm medication is so effective, recurrent tapeworm infections are almost always due to re-infection from fleas and not failure of the product.



### ***Can I get tapeworms from my dog?***

Contracting tapeworms from your dog is not common or likely. *Dipylidium caninum*, the most common tapeworm of the dog, depends on the flea as the intermediate host. A person must swallow an infected flea to become infected. A few cases of tapeworm infection have been reported in children. Vigorous flea control will also eliminate any risk of children in the environment becoming infected.

Although *Dipylidium* species are the most common tapeworms in dogs, other Cestodes are also important in certain areas.

***Taenia species*** – These are tapeworms are acquired by eating prey or waste containing the infective larval stage. These are much larger tapeworms, often up to one yard (one meter) in length. Intermediate hosts include rodents, rabbits, hares and sheep. The intermediate stages develop hydatid cysts in various organs. We have excellent treatment for *Taenia* infections in dogs.

***Echinococcus species*** – By contrast, these are very small tapeworms. They consist of only three or four segments and are usually less than 3/8" (1 cm) in length. Intermediate hosts can be sheep, horses and occasionally man. Infection is by ingesting eggs that have originated from

the feces of dogs or foxes harboring the adult tapeworm. Fortunately de-worming preparations, particularly those containing praziquantel are effective for eliminating the Cestode from the dog.

Control measures to prevent tapeworm infection from Cestodes involve avoidance of uncooked or partially cooked meat or waste.

---

*This client information sheet is based on material written by Ernest Ward, DVM.  
© Copyright 2005 Lifelearn Inc. Used with permission under license. May 23, 2014*