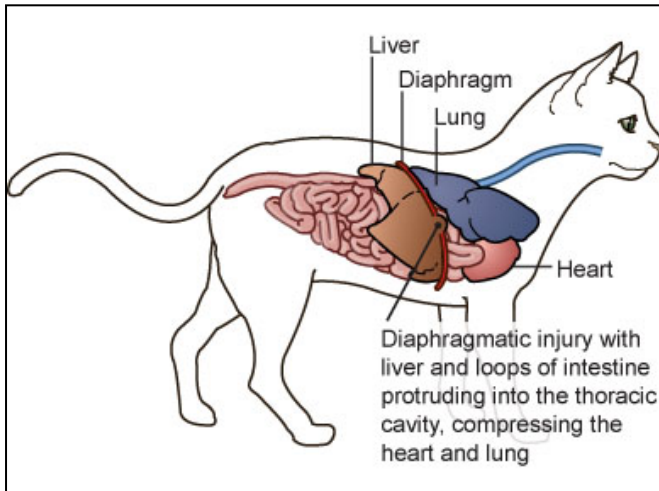


Diaphragmatic Hernia in Cats

What is a diaphragmatic hernia?

The diaphragm is the muscular partition that separates the abdomen and the chest. Tearing or disruption of this thin muscle is called a diaphragmatic hernia or diaphragmatic rupture. The terms can be used synonymously with diaphragmatic hernia incorporating congenital forms such as peritoneal-pericardial diaphragmatic hernia (PPDH).

PPDH may be due to defective development of the fetus. This condition is most often found in puppies or kittens and should be considered separately from the traumatic type of diaphragmatic herniation or rupture.



Once a tear in the diaphragm is present, abdominal contents such as the stomach, liver, and intestines may enter the chest cavity. The abdominal contents compress the lungs and prevent them from fully inflating, resulting in respiratory distress known as dyspnea. The

irritation to the heart muscle often causes abnormal heart rhythms. Fluid may leak into the chest cavity further complicating and worsening cardiopulmonary function.

What causes a diaphragmatic hernia or rupture?

The most common cause of diaphragmatic hernia is trauma. Pets that fall from high places, are struck by automobiles, are kicked in the abdomen or suffer other forms of blunt trauma are likely to rupture their diaphragm. Congenital diaphragmatic hernias are the other major cause seen in veterinary hospitals.

What are the clinical signs of diaphragmatic hernia?

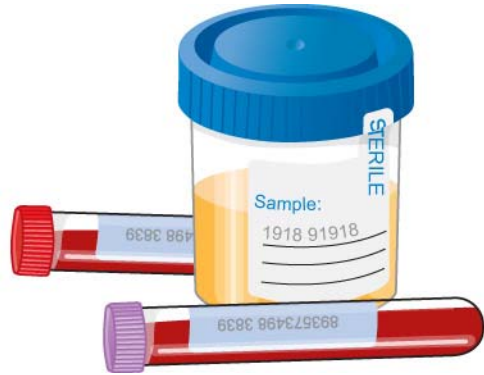Clinical signs are dependent on the severity of herniation. With small tears or in cats born with a diaphragmatic hernia, there may be no discernable clinical signs. Many pet owners report mild breathing difficulties, especially when stressed, and periods of mild gastrointestinal upset. In severe or acute cases, there is often respiratory distress, systemic shock, abnormal heart rhythms, and muffled heart and lung sounds. The abdomen may feel empty when palpated.

How is a diaphragmatic hernia diagnosed?

Diagnosis is based on medical history, physical examination and radiographs. Blood and urine tests may be performed in cases of shock. In certain cases, ultrasound or special radiographic dye studies will be required for definitive diagnosis.

What is the treatment for diaphragmatic hernia?

Treatment is first directed at stabilizing the patient if trauma has recently occurred. Some patients will require immediate thoracocentesis to remove any fluid that is accumulating in the chest cavity. Once the patient is stabilized and a diagnosis is made, the hernia must be corrected surgically. In congenital forms, surgical intervention as early as possible is important to prevent organ entrapment or scarring between the intestines and the chest cavity. Many congenital diaphragmatic hernias are discovered during ovariohysterectomy (spaying) and are corrected at that time.



What is the prognosis?

The prognosis for any patient with diaphragmatic hernia is always initially guarded. It improves if the patient is able to be stabilized and if the heart rhythm is normal. After surgery, the risk of a condition called re-expansion pulmonary edema requires that a guarded prognosis be given for at least twenty-four hours after successful surgery. The prognosis for young pets with congenital diaphragmatic hernia is guarded to good, based on the specific findings during surgical correction.

If the patient stabilizes with medical treatment, is it possible to avoid surgery?

In trauma cases, adhesions may form between the lungs and any herniated abdominal contents after approximately seven days. These adhesions will affect the ability of the lungs to inflate properly, and will cause the surgery to become more complicated and dangerous. However, each case needs to be assessed individually.